

The morpho-functional assessment of plasmonic photothermal therapy effects on transplanted liver tumor

A. B. Bucharskaya^{*,||}, G. N. Maslyakova^{*}, G. A. Afanasyeva^{*}, G. S. Terentyuk^{*,†},
N. A. Navolokin^{*}, O. V. Zlobina^{*}, D. S. Chumakov[†], A. N. Bashkatov[†], E. A. Genina[†],
N. G. Khlebtsov^{†,‡}, B. N. Khlebtsov[‡] and V. V. Tuchin^{†,§,¶}

^{*}*Saratov State Medical University n.a. V.I. Razumovsky, Russia*

[†]*Saratov State University n.a. N.G. Chernyshevsky, Russia*

[‡]*Institute of Biochemistry and Physiology of Plants and
Microorganisms RAS, Saratov, Russia*

[§]*Institute of Precise Mechanics and Control RAS, Saratov, Russia*

[¶]*Optoelectronics and Measurement Techniques Laboratory
University of Oulu, Oulu, Finland*

^{||}*allaalla_72@mail.ru*

Received 7 March 2014

Accepted 26 May 2014

Published 1 July 2014

The antitumor efficiency of gold nanorod plasmonic photothermal therapy (PPTT) was evaluated experimentally. The rat cholangiocarcinoma line PC-1 was used as a tumor model. Exposure of tumors to 808-nm laser radiation was performed, and the noninvasive temperature monitoring of the tumor tissue was carried out using infrared imager. The growth rate kinetics and morphological alterations of transplanted liver tumors, as well as indicators of lipid peroxidation activity and autointoxication in rat serum, were studied. The activation of lipid peroxidation and the development of autointoxication were detected after PPTT. The results not only demonstrate the antitumor efficacy of the proposed therapeutic technology but also reveal the side effects in the presence of peroxidation products in systemic circulation.

Keywords: Gold nanorods; plasmonic photothermal therapy; laser hyperthermia; transplanted liver tumor.

1. Introduction

Currently the development of novel medical technologies that can improve the results of treatment of malignant tumors is the urgent area of research.

One of the well established approaches for cancer treatment is laser-induced interstitial thermo-therapy (LIIT).^{1,2} The major drawback of LIIT is its low spatial selectivity at tissue heating, affecting

This is an Open Access article published by World Scientific Publishing Company. It is distributed under the terms of the Creative Commons Attribution 3.0 (CC-BY) License. Further distribution of this work is permitted, provided the original work is properly cited.

both tumor and surrounding healthy tissue. The selectivity can be significantly increased at staining a target tissue by indocyanine green dye. This photothermal therapy technology was pioneered by Chen and nowadays it is used in combination with the immunoadjuvant that helps to enhance therapeutic efficiency of cancer treatment.³ Another way to improve the selectivity of laser treatment is to use a photothermal sensitization of tumor tissues by gold nanoparticles of different shapes and structures.^{4–14} For applications in medicine, the resonant optical properties of nanostructures should be configured to fit the wavelength range of transparency window of biological tissues.¹⁵ Spectral tuning of plasmon resonance of nanoparticles and the relation between their absorption and scattering was implemented by changing the size, shape, form and structure of the nanoparticles.¹⁴

At irradiation of tumor tissue by a laser with the wavelength close to the particle plasmon absorption band, thermolysis of tumor cells labeled by nanoparticles can be achieved, while the surrounding healthy tissues remain intact.^{7–10} Such technology has been developed over the last decade and it was named a plasmonic photothermal therapy (PPTT).¹⁶ The possibility of spectral tuning of plasmon resonance of nanoparticles in the “therapeutic window of transparency” and achieving an acceptable ratio between their absorption and scattering efficiencies was reported.^{14,17}

Gold nanorods have a high brightness and increased sensitivity of resonant scattering to the dielectric environment as compared with equivolume spheres. The main optical resonance of nanorods is easily adjusted by changing their axial ratio.¹⁸ It causes promising prospects of their use for optical photothermolysis of tumor cells.

A number of authors^{19–21} have shown that excessive formation of free radicals and inactivation of antioxidant enzyme on the background of antitumor laser therapy ensures the accumulation of toxic products of oxidative stress intensifying the severity of endogenous tumor intoxication. Secondary metabolic disorders are accompanied by toxic damage of cell membranes of various internal organs and tissues, which is often the limiting factor for further treatment. Therefore, it is necessary to assess the effectiveness and safety of new method of selective laser hyperthermia of malignant tumors.

The objectives of our work were to identify the morphological changes in the internal organs and

transplanted liver tumors and to assess the degree of autointoxication of laboratory animals exposed to PPTT.

2. Methods and Materials

Animal experiments were performed in accordance with the guidance (International Guiding principles for Biomedical Research Involving Animals).²² A total of 30 male outbred albino rats weighing 160 ± 20 g were used to study the effect of laser hyperthermia with a single intratumoral injection of gold nanorods. 0.5 mL of 25% tumor cell suspension of alveolar liver cancer — cholangiocarcinoma PC-1, obtained from the bank of tumor strains of Russian Cancer Research Center n.a. N.N. Blokhin (Moscow, Russia), was implanted subcutaneously in rats. When the tumor reached a diameter of 1.0 ± 0.3 cm, the animals were randomly divided into three groups (10 rats in each group): group 1 without exposure (comparison group), group 2 with the laser irradiation of the tumor, group 3 with intratumoral administration of gold nanorods and laser irradiation of the tumor. As control group 10 nontumor bearing animals were used.

Gold nanorods were synthesized by previously established method.¹⁸ To prevent nanoparticles aggregation in biological tissue and enhance biocompatibility, nanoparticles were functionalized with thiolated polyethyleneglycol (Mw = 5000, Nektar, USA) by previously established method.²³ Geometrical parameters of gold nanorods were determined from analysis of transmission electron microscopy (TEM) images (Libra-120, Carl Zeiss, Germany) by using standard graphic editor.

Extinction spectrum of the sample was measured with a Specord 250 BU spectrophotometer (Analytik, Jena, Germany). Before measurements, the nanorods suspension was diluted to 1:10 and was placed in 2 mm quartz cuvette.

Nanorods zeta-potential measurements were made with a Zetasizer Nano-ZS instrument (Malvern, UK). In a good agreement with previously reported data,²³ pegilated nanorods have slightly negative zeta-potential (-14 mV).

The infrared 808-nm CW laser LS-2-N-808-10000 (Laser Systems, Ltd., St. Petersburg, Russia) at a power density of 2.3 W/cm² was used for PPTT. The area of the laser spot on the skin surface was about 0.5 cm². An hour before laser irradiation, the

animals were injected intratumorally with the solution of gold nanorods in the amount of 30% of the tumor volume.

The injection of the gold nanoparticles directly into the tumor was conducted according to the paper of Xie and co-workers,²⁴ where the authors demonstrated that using such a modification of intratumoral injection leads to prolonged retention of nanoparticles in tumor tissue.

Size of the nanorods was 41 ± 8 nm long and 10 ± 2 nm wide and concentration of nanorods in the suspension was 400 pg/mL, which corresponds to optical density of 20 at this wavelength. Irradiation was carried out percutaneously within the area of a tumor during 15 min. Temperature control of the tumor heating was provided by IR imager IRI4010, Infrared Integrated System (IRYSYS, UK).

Prior to any medical procedure or treatment, the rats were anaesthetized with Zoletil 50 (Virbac, France) in dose of 0.05 mg/kg. The removal of animal from the experiment was performed 24 h after laser exposure. The tissue samples of internal organs and tumors for morphological studies were collected. The standard histological techniques with hematoxylin and eosin staining were used.

The study of lipid peroxidation activity was carried out using measuring of intermediate products of lipid peroxidation — malondialdehyde (MDA) and lipid hydroperoxide (GPL) — in the blood serum of experimental animals with standard biochemical methods on spectrofluorometer RF-5301 PC (Shimadzu Corp., Japan). MDA was determined by reaction with 2-thiobarbituric acid. The absorbance of samples was measured by spectrophotometric

recording at $\lambda = 532$ nm, the concentration of MDA was expressed in $\mu\text{M}/\text{mL}$. The method of hydroperoxide determination was based on absorption of ultraviolet radiation by lipid hydroperoxide at the wavelength of 233 nm. The results were expressed in relative optical density units per 1 mL of plasma. The severity of autointoxication was assessed by integrative indicator — the level of average mass molecules (AMM) in the blood serum of rats. The coarse serum proteins were precipitated by adding 10% trichloroacetic acid solution which was centrifuged for 20 min at 3000 rev/min. The supernatant was then examined in a spectrophotometer at the wavelength of 254 nm. The results were expressed in relative optical density units per 1 mL of plasma.²⁵

3. Results and Discussion

As shown in Fig. 1(a), the average particle shape corresponds to cylinders with hemispherical ends. The number of particles with another shape, such as with flat ends and lesser particle diameter for the nanorod middle was very small. Length, diameter and the axial ratio of each particle were determined for an ensemble of about 500 particles. Average values for the length and diameter of rods were 41 ± 8 nm and 10.2 ± 2 nm, respectively. Such geometrical parameters lead to strong plasmon resonance in NIR region (810–820 nm). In agreement with this speculation, the longitudinal resonances are located near 810 nm [Fig. 1(b)]. The ratio of major to minor resonance maximum equals indicating that the percentage of impurity particles (sphere, cubes, etc.) is small.¹⁸ On the other hand,

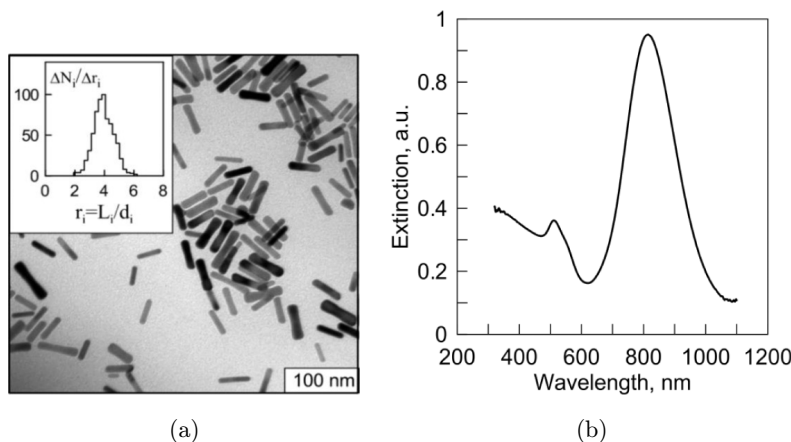


Fig. 1. (a) TEM image of gold nanorods. The insert in Fig. 1(a) shows the histogram of the numerical distribution of the particles $\Delta N_i/\Delta r_i$ on the axial ratio $r_i = L_i/d_i$ with the average value $r = 4.03 \pm 0.7$. (b) Extinction spectrum of gold nanorod suspension.

Table 1. Indicators of lipid peroxidation and autointoxication of rats.

Experimental groups	MDA (micromoles/mL)		Lipid hydroperoxide (units/mL)		AMM (units/mL)	
	$M \pm m$	p	$M \pm m$	p	$M \pm m$	p
Control group	0.506 ± 0.023	—	0.924 ± 0.099	—	0.159 ± 0.014	—
Liver tumor	0.928 ± 0.104	$p < 0.001$	2.503 ± 0.290	$p < 0.001$	0.269 ± 0.020	$p < 0.001$
Liver tumor after laser hyperthermia	0.815 ± 0.079	$p < 0.001$ $p1 > 0.5$	2.204 ± 0.217	$p < 0.001$ $p1 > 0.2$	0.368 ± 0.032	$p < 0.001$ $p1 < 0.01$
Liver tumor after PPTT	1.473 ± 0.105	$p < 0.001$ $p1 < 0.001$ $p2 < 0.001$	2.780 ± 0.320	$p < 0.001$ $p1 > 0.5$ $p2 > 0.1$	0.375 ± 0.029	$p < 0.001$ $p1 < 0.001$ $p2 > 0.5$

Note: p — was counted compared with control group; $p1$ — was counted compared with liver tumor group; $p2$ — was counted compared with liver tumor group after laser hyperthermia; M — average value; m — standard deviation.

the full width at half maximum (FWHM) is about 200 nm, which is typical of the moderate polydispersity of Au NRs over length and width.

The inset in Fig. 1(a) shows the histogram of the numerical distribution of the particles $\Delta N_i/\Delta r_i$ on the axial ratio $r_i = L_i/d_i$ with the average value $r = 4.03 \pm 0.7$.

Morphologically tumors in the comparison group of rats had a lobed structure; segments were separated by thin layers of connective tissue. Tumor cells had oval-rounded shape with eccentrically located nuclei. A significant portion of cytoplasm was occupied by large vacuoles containing mucus. There were clusters of mucous masses in the intercellular spaces.

Simultaneously, a significant increase in the level of MDA ($p < 0.001$), GPL ($p < 0.001$) and AMM ($p < 0.001$) was found in the serum as compared with those in the group of nontumor bearing animals. This indicates the activation of lipid peroxidation and the development of autointoxication in experimental animals with cholangiocarcinoma (Table 1).

In morphological studies of animals with cholangiocarcinoma, there were no changes in the liver, kidney and spleen in comparison with the control group. The study of liver tissue demonstrated that architectonic structure was intact, the moderate congestion in small capillaries and necrosis of individual hepatocytes were observed after laser hyperthermia. The moderate congestion in large vessels and necrosis of individual hepatocytes were detected in the liver after PPTT with gold nanorods (Fig. 2).

In kidney, moderate congestion in the glomeruli and foci of hemorrhage between the tubules were observed after laser hyperthermia. Foci of hemorrhage, the swelling between the capsule of glomerulus, large full-blooded vessels were observed after PPTT (Fig. 3).

The morphological changes were not pronounced in the organs of detoxification because of the short time between the start of exposure and deducing animals from the experiment.

In spleen, after laser hyperthermia, the signs of lymphoid cell activation were not observed in the

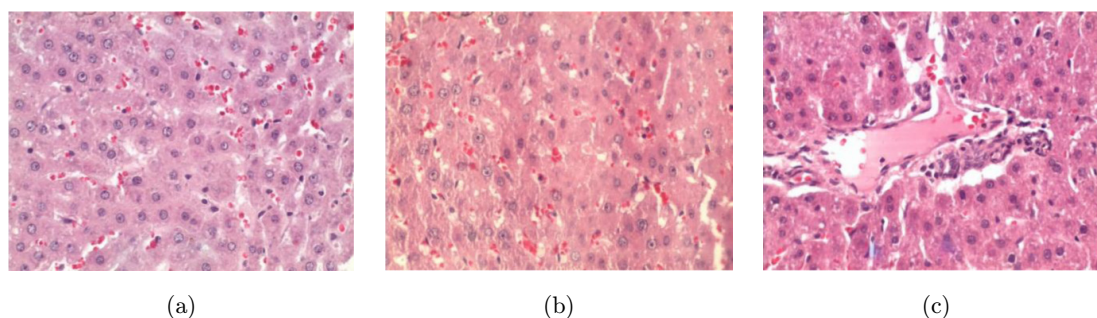


Fig. 2. Histological sections of liver: (a) Comparison group (rats with PC-1). The moderate congestion of the capillaries. (b) Group with laser hyperthermia. The necrosis of individual hepatocytes. (c) Group with PPTT. The hepatocyte necrosis. Extension of vein of portal tract. The blood separation phenomenon — Staining with hematoxylin and eosin. ($\times 400$).

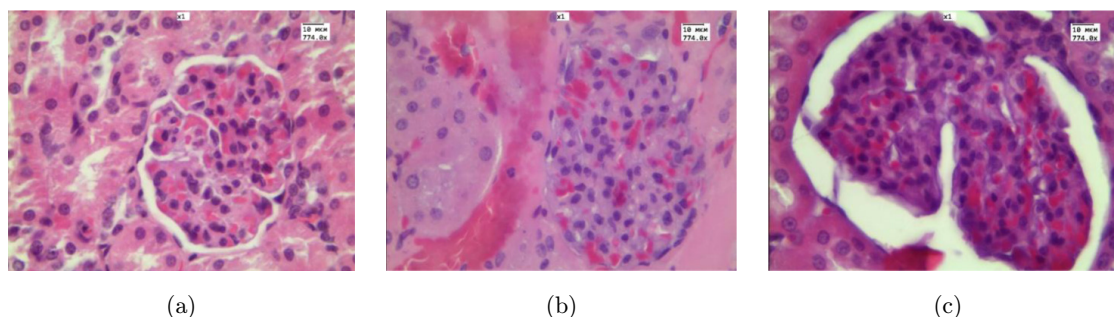


Fig. 3. Histological sections of kidney: (a) Comparison group (rat with PC-1). The moderate congestion in the glomeruli. (b) Group with laser hyperthermia. The moderate congestion in the glomeruli, foci of hemorrhage between the tubules. (c) Group with PPTT. The swelling between the capsule of glomerulus. Staining with hematoxylin and eosin. ($\times 774$).

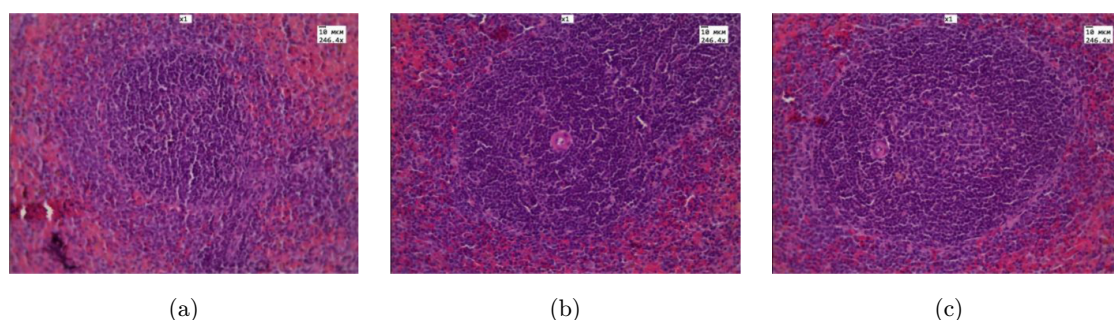


Fig. 4. Histological sections of spleen: (a) Comparison group (rats with PC-1). Lymphoid follicle of the spleen; (b) Group with laser hyperthermia. Increase of periarterial zone of lymphoid follicle of the spleen. (c) Group with PPTT. The germinal center of lymphoid follicle. Staining with hematoxylin and eosin. ($\times 246, 4$).

white pulp. Increasing of follicles with germinal center and density of lymphoid cells in periarterial zone (Fig. 4), as well as immunoblast predominance were observed in spleen after PPTT with gold nanoparticles. These changes in spleen are a sign of the immune system activation.

At only laser exposure, the tumor temperature increased up to 42°C . The morphologic study of tumors in group 2 (only laser treatment) proved that the tumor maintained a lobed structure. A small foci of necrosis were noted (5–10% of the total area of tissue); the necrotic changes in the tumor cells occurred; the single mitosis was identified; the vessels were full blooded. Thickening of the connective tissue septa, infiltration of leukocytes and focal hemorrhages were observed [Figs. 5(c) and 5(d)].

At the same time MDA, GPL and AMM levels were still significantly higher than those control indicators. The absence of significant morphological changes in the tumor in this series of experiments was accompanied by preservation of the activity of lipid peroxidation processes. However, the level of AMM grew progressively (Table 1).

We noted a significant increase in tumor temperature (up to 60°C) in experiment with PPTT of tumors — using laser irradiation and gold nanorods as nanosensitizers. The pronounced necrotic changes developed in the tumor center, which occupied up to 80–90% of the slice. The tumor cells with marked degenerative changes were located in sub-capsular tumor zone [Figs. 5(e) and 5(f)].

The formation of local necrosis in organs and tissues was accompanied by the development of systemic toxicity and metabolic disorders in the body. In a series of experiments on animals with cholangiocarcinoma, the excessive accumulation of MDA ($p2 < 0.001$) was revealed in the serum of rats after PPTT exposure compared with group of animals exposed to laser irradiation without the use of nanoparticles.

The growth of cholangiocellular cancer is accompanied by increase of the lipid peroxidation activity and the development of severe autointoxication compared to intact animals. This is confirmed by an increase in the content of the intermediate products of lipid peroxidation — MDA and the GPL — and

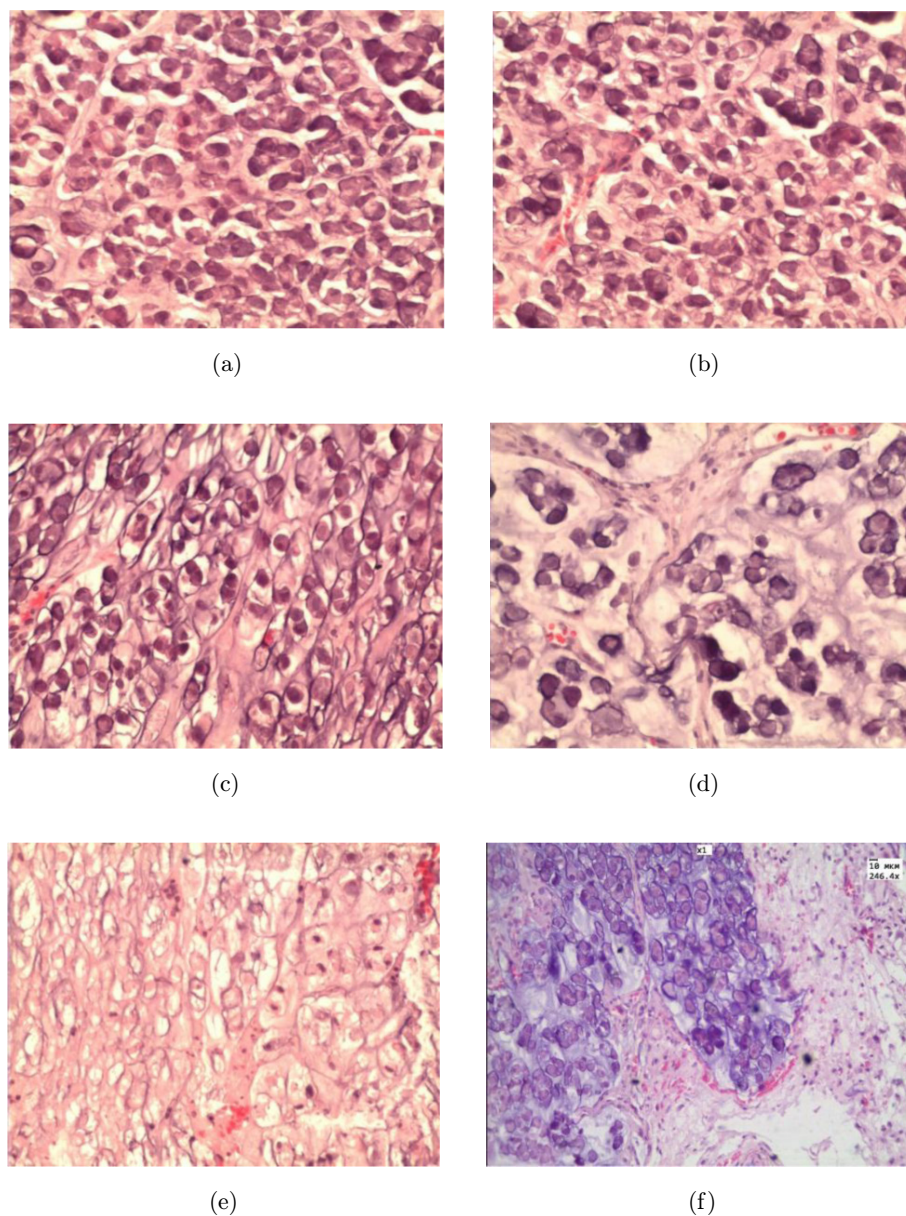


Fig. 5. Histological sections of a liver tumor: (a), (b) Comparison group (rats with PC-1). Tumor lobe with intact tumor cells. (c), (d) Group with laser hyperthermia. (c) Tumor lobe with degenerative changes of cells. (d) The leukocyte infiltration of the connective tissue septa, congestion of vessels. (e), (f) Group with PPTT. (e) Pronounced necrosis in tumor center. (f) The dystrophic changes in the tumor cells of subcapsular zone. Hematoxylin and eosin. ($\times 774$).

the accumulation of AMM excess in serum. The obtained results are consistent with literature data, indicating that tumor growth in the body violates oxidative balance and causes activation of free radical oxidation.^{17,21} These shifts are due to changes occurring on the stages of transformation of tumor cells, tumor progression and promotion at the local and systemic levels, as well as associated with the manifestations of functional, biochemical and morphological atypia of tumor cells.

In previous experiments, we found there were no significant differences of morphofunctional features in group of tumor bearing animals after single intratumoral injection of gold nanorods.

Our data on the activation of free radical oxidation in the blood serum of animals after using PPTT are consistent with the results of the authors,^{19–21} who discovered the intensification of lipid peroxidation, a progressive increase in lipid peroxidation products in the serum of patients

with malignant neoplasms after complex therapy including surgery, radiation therapy and adjuvant combination chemotherapy.

Activation of free lipid accumulation in animal serum lipid peroxidation products as a result of exposure to laser radiation on the tumor may have an ambiguous interpretation. Free radical destabilization of biological membranes of cells exposed to laser hyperthermia shows cytolytic effect on tumor cells and confirms the effectiveness of the treatment with using nanosensitizers according to Wang.²⁶

At the same time, the radiation effect along with the cytotoxic effect on malignant cells may provide a pronounced cytotoxic effect on cells of various tissues and organs outside the tumor. Formation system paraneoplastic metabolic disorders in the form of accumulation of lipid peroxidation products in the systemic circulation as a result of laser hyperthermia can significantly intensify the severity of the disease and contribute to the development of secondary dysfunctions of organs and body systems on the background of autointoxication.

In this regard, it seems promising to study the application of antihypoxants, antioxidants, membrane protectors and immunoadjuvant to improve the effectiveness of PPTT therapy for malignant tumors.

4. Conclusion

The most pronounced necrotic processes in the tumor tissue were detected after PPTT with gold nanorods as nanosensitizers. The accumulation of intermediate products of lipid peroxidation and the development of autointoxication were revealed after PPTT with gold nanorods that may be the leading pathogenetic factors that can result in damage of membranes of tumor cells at PPTT. The results not only demonstrate the antitumor efficacy of the proposed therapeutic technology but also reveal side effects in the presence of peroxidation products in systemic circulation.

Acknowledgments

The work by NGK and BNK on synthesis and characterization of nanoparticles was supported by a grant No. 14-13-01167 from the Russian Scientific Foundation. The optical part of this study was supported by the Russian Presidential

grant NSh-703.2014.2 (ANB, EAG and VVT). The histological studies by ABB, GNM and GST was supported by a grant No. 14.Z50.31.0004 to support scientific research projects implemented under the supervision of leading scientists at Russian institutions of higher education.

References

1. G. Müller, A. Roggan (Eds.), *Laser-Induced Interstitial Thermotherapy*, SPIE Press, Bellingham, WA (1995).
2. A. J. Welch, M. J. C. van Gemert (Eds.), *Optical-Thermal Response of Laser-Irradiated Tissue*, 2nd Edition, Springer-Verlag, Berlin, Heidelberg, NY (2011).
3. X. Li, T. Hode, M. C. Guerra, G. L. Ferrel, J. A. Lunn, O. Adalsteinsson, R. E. Nordquist, W. R. Chen, "Combined effects of selective photothermal therapy and immunoadjuvant against stage IV breast cancer," *J. Innov. Opt. Health Sci.* **3**(4), 279–284 (2010).
4. L. R. Hirsh, R. J. Stafford, J. A. Bankson, S. R. Sershen, B. Rivera, R. E. Price, J. D. Hazle, N. J. Halas, J. L. West, "Nanoshell-mediated near-infrared thermal therapy of tumors under magnetic resonance guidance," *Proc. Natl. Acad. Sci. U.S.A.* **100**(23), 13549–13554 (2003).
5. G. S. Terentyuk, I. L. Maksimova, V. V. Tuchin, V. P. Zharov, B. N. Khlebtsov, V. A. Bogatyrev, L. A. Dykman, N. G. Khlebtsov, "Application of gold nanoparticles to X-ray diagnostics and photothermal therapy of cancer," *Proc. SPIE* **6536**, 65360B (2006).
6. E. B. Dickerson, E. C. Dreaden, X. Huang, I. H. El-Sayed, H. Chu, S. Pushpanketh, J. F. McDonald, M. A. El-Sayed, "Gold nanorod assisted near-infrared plasmonic photothermal therapy (PPTT) of squamous cell carcinoma in mice," *Cancer Lett.* **269**(1), 57–66 (2008).
7. X. Huang, P. K. Jain, I. H. El-Sayed, M. A. El-Sayed, "Plasmonic photothermal therapy (PPTT) using gold nanoparticles," *Lasers Med. Sci.* **23**(3), 217–228 (2008).
8. G. S. Terentyuk, G. N. Maslyakova, L. V. Suleymanova, N. G. Khlebtsov, B. N. Khlebtsov, G. G. Akchurin, I. L. Maksimova, V. V. Tuchin, "Laser-induced tissue hyperthermia mediated by gold nanoparticles: Toward cancer therapy," *J. Biomed. Opt.* **14**(2), 021016.
9. G. S. Terentyuk, G. N. Maslyakova, L. V. Suleymanova, B. N. Khlebtsov, B. Ya. Kogan, G. G. Akchurin, A. V. Shantrocha, I. L. Maksimova, N. G. Khlebtsov, V. V. Tuchin, "Circulation and

- distribution of gold nanoparticles and induced alterations of tissue morphology at intravenous particle delivery," *J. Biophotonics* **2**(5), 292–302 (2009).
10. G. S. Terentyuk, G. G. Akchurin, I. L. Maksimova, G. N. Maslyakova, N. G. Khlebtsov, V. V. Tuchin, "Cancer laser thermotherapy mediated by plasmon nanoparticles," *Handbook of Photonics for Biomedical Science*, Chapter 29, V. V. Tuchin (Ed.), pp. 763–797, CRC Press, Taylor & Francis Group, London (2010).
 11. E. Y. Lukianova-Hleb, E. Y. Hanna, J. H. Hafner, D. O. Lapotko, "Tunable plasmon nanobubbles for cell theranostics," *Nanotechnology*. **21**(8), 085102 (2010).
 12. H. Yuan, C. G. Khoury, C. M. Wilson, G. A. Grant, A. J. Bennett, T. Vo-Dinh, "In vivo particle tracking and photothermal ablation using plasmon-resonant gold nanostars," *Nanomedicine* **8**(8), 1355–1363 (2012).
 13. G. S. Terentyuk, I. L. Maksimova, N. I. Dikht, A. G. Terentyuk, B. N. Khlebtsov, N. G. Khlebtsov, V. V. Tuchin, "Cancer laser therapy using gold nanoparticles," *Lasers for Medical Applications: Diagnostics, Therapy and Surgery*, Chapter 22, H. Jelinkova (Ed.), Electronic and Optical Materials Series No. 37, pp. 659–703, Woodhead Publishing, Ltd., Cambridge (2013).
 14. N. G. Khlebtsov, "Optics and biophotonics of nanoparticles with a plasmon resonance," *Quantum Electron.* **38**(6), 504–529 (2008).
 15. A. N. Bashkatov, E. A. Genina, V. V. Tuchin, "Optical properties of skin, subcutaneous, and muscle tissues: A review," *J. Innov. Opt. Health Sci.* **4**(1), 9–38 (2011).
 16. X. Huang, P. K. Jain, I. H. El-Sayed, M. A. El-Sayed, "Gold nanoparticles and nanorods in medicine: From cancer diagnostics to photothermal therapy," *Nanomedicine* **2**, 681–693 (2007).
 17. N. Harris, M. J. Ford, M. B. Cortie, "Optimization of plasmon heating by gold nanospheres and nanoshells," *J. Phys. Chem. B* **110**(22), 10701–10707 (2006).
 18. A. V. Alekseeva, V. A. Bogatyrev, B. N. Khlebtsov, A. G. Melnikov, L. A. Dykman, N. G. Khlebtsov, "Gold nanorods: Synthesis and optical properties," *Colloid J.* **68**(6), 661–678 (2006).
 19. D. Chang, F. Fang, Y. S. Zhao, H. Z. Pan, "Evaluation of oxidative stress in colorectal cancer patients," *Biomed. Environ. Sci.* **21**(4), 286–289 (2008).
 20. M. L. Looi, M. Dali, A. Z. Hatta, M. Ali, S. Aishah, W. Ngah, W. Zurinah, M. Yusof, Y. Anum, "Oxidative damage and antioxidant status in patients with cervical intraepithelial neoplasia and carcinoma of the cervix," *Eur. J. Cancer Prev.* **17**(6), 555–560 (2008).
 21. C. P. Rajneesh, A. Manimaran, K. R. Sasikala, P. Adaikappan, "Lipid peroxidation and antioxidant status in patients with breast cancer," *Singapore Med. J.* **49**(8), 640–643 (2008).
 22. International Guiding Principles for Biomedical Research Involving Animals, *CIOMS&ICLAS* (2012), Available at <http://www.cioms.ch/index.php/12-newsflash/227-cioms-and-iclas-release-the-new-international-guiding-principles-for-biomedical-research-involving-animals>.
 23. B. N. Khlebtsov, E. S. Tuchina, V. A. Khanadeev, E. V. Panfilova, P. O. Petrov, V. V. Tuchin, N. G. Khlebtsov, "Enhanced photoinactivation of *Staphylococcus aureus* with nanocomposites containing plasmon particles and hematoporphyrin," *J. Biophotonics* **6**(4), 338–351 (2013).
 24. H. Xie, B. Goins, A. Bao, Z. J. Wang, W. T. Philips, "Effect of intratumoral administration on biodistribution of 64 Cu-labeled nanoshells," *Int. J. Nanomedicine* **7**, 2227–2238 (2012).
 25. A. I. Karpishchenko (Ed.), *Medical Laboratory Technology*, p. 600, St. Petersburg: Intermedika 2002.
 26. J. Wang, J. Yi, "Cancer cell killing via ROS: To increase or decrease, that is the question," *Cancer Biol. Ther.* **7**(12), 1875–1884 (2008).